

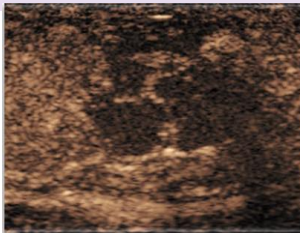
Sofia Pagani Soares Pinto⁽¹⁾, Kamran Ahmed⁽¹⁾, Paul S. Sidhu⁽²⁾, Dean Y. Huang⁽²⁾

1. MRC Centre for Transplantation, King's College London, London, United Kingdom

2. Dept. of Clinical Radiology, King's College Hospital, London, United Kingdom

Introduction & Aims

It is essential to correctly differentiate testicular lesions in order to provide appropriate treatment. Greyscale ultrasound (US) and colour Doppler ultrasound (CDUS) are the primary investigations for such lesions. Although able to characterise most lesions, they are limited in their assessment of the microvasculature, an important feature in the distinction of non-neoplastic from neoplastic lesions. **Contrast-enhanced ultrasound (CEUS)** uses an **exclusively intravascular contrast agent**, allowing accurate visualisation of the microvasculature.



This review aims to **evaluate the use of CEUS in the context of multiparametric ultrasound (MPUS)** in differentiating non-neoplastic from neoplastic lesions and benign from malignant neoplasms, and to **assess the diagnostic performance** of MPUS.

Methods



- **Retrospective** single centre study
- **Index test** – MPUS including CEUS, **Reference test** – histology (gold standard) or > 3 month follow-up



- **Inclusion criteria:** MPUS investigation for intra-testicular lesions from 2016 to 2019
- **Exclusion criteria:** follow-up < 3 months, lack of information on diagnosis and management



- **Data source:** radiology reports written after MPUS investigation and clinical data from electronic patient records
- **Data collected:** on patient and lesion characteristics on MPUS, diagnostic impression, final diagnoses



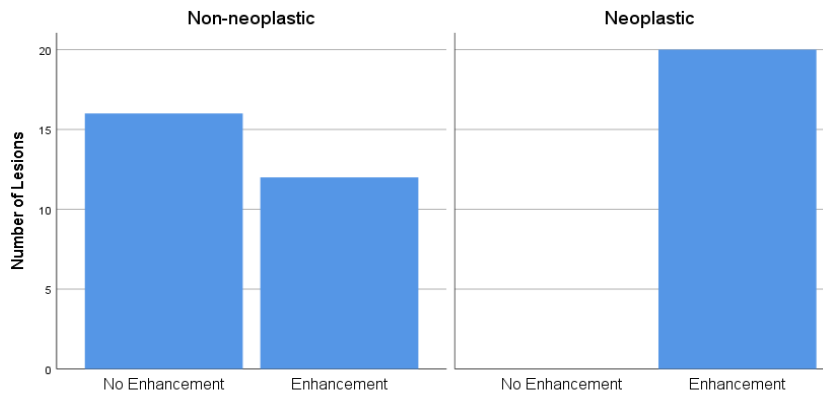
- **Statistics:** Pearson's Chi Square/Fisher's Exact Test; sensitivity, specificity, PPV and NPV for diagnostic performance

Conclusions

- **MPUS performs well as a diagnostic test** with high sensitivity and specificity for testicular malignancy.
- Lack of enhancement on CEUS **confirms non-neoplastic lesions**
- **Enhancement alone is unable to differentiate benign from malignant neoplasms** as benign lesions such as Leydig cell tumours with low malignant potential also show enhancement
- **Clinical implications:** MPUS including CEUS has a role in investigating testicular lesions and the 3 modalities combined provide greater certainty
- **Future research:** Role of quantitative CEUS in differentiating benign from malignant neoplasms as there are currently very few studies
- **Limitations:** Retrospective study, image characteristics collected from reports, small sample size, selection bias (neoplasms more likely to be selected).

Results

CEUS Enhancement in Non-neoplastic and Neoplastic Lesions



Forty-nine patients with 29 non-neoplastic, 10 benign neoplastic, and 10 malignant neoplastic lesions.

Contrast-enhanced ultrasound Features

- Enhancement on CEUS is associated with neoplastic lesions when compared to non-neoplastic lesions ($p < 0.01$). All neoplastic lesions enhanced and it is not possible to differentiate benign from malignant neoplasms with enhancement.

Diagnostic Performance

- Sensitivity, specificity, positive predictive value (PPV) and negative predictive value (NPV) are shown for the performance of MPUS in identifying neoplastic from non-neoplastic lesions and malignant from benign neoplasms.

Test	Sensitivity (95% CI)	Specificity (95% CI)	PPV (95% CI)	NPV (95% CI)
Neoplastic vs Non-neoplastic	100% (83-100)	86% (68-96)	83% (67-93)	100% (N/A)
Malignant vs Benign	90% (56-100)	60% (26-88)	69% (51-83)	86% (47-98)

References

1. Huang DY, Sidhu PS. Focal testicular lesions: colour Doppler ultrasound, contrast-enhanced ultrasound and tissue elastography as adjuvants to the diagnosis. *Br J Radiol.* 2012;85 Spec No 1:S41-53.
2. Berlotto M, Muca M, Curro F, Bucci S, Rocher L, Cova M. Multiparametric US for scrotal diseases. *Abdominal Radiology.* 2018:899-917.
3. Isidori AM, Pozza C, Gianfrilli D, Giannetta E, Lemma A, Pofi R, et al. Differential diagnosis of nonpalpable testicular lesions: qualitative and quantitative contrast-enhanced US of benign and malignant testicular tumors. *Radiology.* 2014;273(2):606-18.
4. Auer T, De Zordo T, Dejaco C, Gruber L, Pichler R, Jaschke W, et al. Value of Multiparametric US in the Assessment of Intratesticular Lesions. *Radiology.* 2017;285(2):640-9.
5. De Zordo T, Stronegger D, Pallwein-Prettner L, Harvey CJ, Pinggera G, Jaschke W, et al. Multiparametric ultrasonography of the testicles. *Nature reviews Urology.* 2013.